

Nanoskin®- The impact of Natural Membrane on COVID-19 and chronic wound

Bassel Safi¹, Mohamed Kanjou¹, Gabriel Molina de Olyveira^{2*}, Pierre Basmaji², Antônio Carlos Guastaldi³

¹Burjeel Hospital., GEM International, Abu Dhabi - Dubai, United Arab Emirates.

²Innovatec's-Biotechnology Research and Development-São Carlos-Brazil.

³UNESP-IQ-Physical Chemistry Department-Araraquara, Brazil.

* **Corresponding Author:** Gabriel Molina de Olyveira, Innovatec's-Biotechnology Research and Development-São Carlos-Brazil.

Received date: 08 March 2022; **Accepted date:** 04 April 2022; **Published date:** 08 April 2022

Citation: Safi B, Kanjou M, de Olyveira GM, Basmaji P, Guastaldi AC (2022) Nanoskin®- The impact of Natural Membrane on COVID-19 and chronic wound. J Comm Med and Pub Health Rep 3(03): <https://doi.org/10.38207/JCMPHR/2022/MAR03030130>

Copyright: © 2022 Gabriel Molina de Olyveira. This is an open-access article distributed under the terms of the Creative Commons Attribution License, which permits unrestricted use, distribution, and reproduction in any medium, provided the original author and source are credited.

Abstract

Bacterial cellulose (BC) is a natural polymer synthesized by some bacteria. As a species of natural biopolymer, BC shows good biological activity, biodegradability and biological adaptability. It has many unique physical, chemical and biological properties, such as ultrafine nanofiber network, high crystallinity, high water absorption and water holding capacity, and high tensile strength and elastic modulus. These excellent properties of BC laid the foundations for its application as a dressing in wound healing. This article describes a behavior investigation of this biomaterial in human medicine with bacterial cellulose in covid-19 and rare skin disease.

Keywords: Bacterial cellulose, Biomaterials, Nanomedicine, Wound healing, COVID-19 wounds.

1. Introduction

Bacterial cellulose (BC) is a natural polymer synthesized by some bacteria. As a kind of natural biopolymer, BC shows good biological activity, biodegradability, and biological adaptability. It has many unique physical, chemical, and biological properties, such as ultra-fine nanofiber network, high crystallinity, high absorption and water holding capacity, and high tensile strength and elastic modulus. These excellent properties of BC laid the foundations for its application as a wound healing dressing. [1,2]

To optimize the biocompatibility and antimicrobial activity of BC, different methods including microbial fermentation, physical modification, chemical modification, and compound modification were adopted to modify BC to ensure better application in wound healing. BC-based dressings have been applied to infected wounds, acute traumatic injuries, burns, and diabetic wounds, showing remarkable therapeutic effects in promoting wound healing. In addition, there have been some commercial BC-based dressings and they have been used in clinical practice.[3,4]

Due to its excellent physicochemical characteristics and biological properties, BC shows high clinical value to be used as a wound dressing for skin tissue regeneration.[3,4]

Bacterial cellulose (BC) produced by aerobic bacteria has the advantages of high purity, high porosity, strong water absorption, high water holding capacity, high mechanical strength, and good biocompatibility.

Advanced wound healing approaches have attracted a lot of attention in recent decades due to the use of new types of dressings that provide a moist environment and take an active part in tissue protection and regeneration processes. Materials for new wound dressings must have

a set of characteristics that will contribute to efficient skin recovery. The use of bacterial cellulose (BC) is attractive for advanced wound management due to the favorable characteristics of BC, such as its biocompatibility, non-toxicity, mechanical stability, and high moisture content. A number of approaches can be taken to modify BC to address the deficiencies of the native material and to optimize its biocompatibility, water absorption and release, and antimicrobial activity. [5,6]

Recent studies showed that the COVID-19 pandemic caused collateral damage in health care in terms of reduced hospital submissions or postponed treatment of other acute or chronic patients. [7,8]

Chronic wounds are commonly related to the same comorbidities that increase the risk for death from infection with severe acute respiratory syndrome coronavirus 2 (SARS-CoV-2). However, risk factors for impaired wound healing and wound complications due to SARS-CoV-2 which is associated with physiologic changes that may affect healing. Whether these changes promote de novo wound development or further impair the healing of chronic wounds in patients infected with COVID-19 is unknown. However, these changes may contribute to the already increased risk for pressure-induced skin and soft tissue injury in patients with COVID-19 who require prolonged hospitalization.[9,10]

It's well known that timely wound care is important to prevent complications and reduce the time to healing. Disruption of wound care paradigms had led to modifications in the delivery of woundcare. [9,10]

Nanoskin® ACT natural extracellular matrix bacterial cellulose (ECM-BC) releases nutrients from bacterial cellulose fermentation to the skin tissue. Produced nanofibers of fermentation have a high concentration of secondary metabolic such as diterpene and alkaloids, that improve skin nutrients and improve the immune system too. [9,10]

Besides, Nanoskin® ACT natural membranes have β-glucan polysaccharide and usnic acid which is an effective antibacterial agent and immunogenic substance. When it is linked to cellular receptors, it increases immune body response. Such natural membranes change

ECM synthesis of new vessels, granulation tissue, and epithelialization that are produced in patient skin. [9,10]

This article highlights possible paths for the functionalization of BC, affecting all levels of its structural organization. The focus is on the post-production treatment of BC, although selected studies referring to in situ modifications during the biosynthesis process are also emphasized. Besides, this article describes a behavior investigation of this biomaterial in human medicine with bacterial cellulose in covid-19 and chronic wounds.

2. Materials and Methods

2.1 Materials

The bacterial cellulose raw material was provided from Innovatec's (São Carlos SP, Brazil). Brassica Nigra extract was purchased from Amazon.

2.2 Methods

2.2.1 Synthesis of Bacterial Cellulose and Brassica Nigra extract

Bacterial cellulose (BC) was produced by fermentation change of Gram-negative bacteria *Gluconacetobacter xylinus*, which will obtain from a culture medium in the pure 3-D structure, consisting of an ultra-fine network of cellulose nanofibers. The acetic fermentation

process was achieved by using glucose as a carbohydrate source and green tea as a nitrogen source. Results of this process were acetic acid and a nanobiocellulose biomass. The modifying process was based on the addition of Brassica Nigra extract(1 % w/w) to the culture medium before bacteria inoculation and after bacterial cellulose hydrogel is dried in an oven to produce bacterial cellulose mats. [9- 13]

2.3) Characterization

In vivo analysis- In vivo wound healing analysis of covid-19 and several chronic wounds.

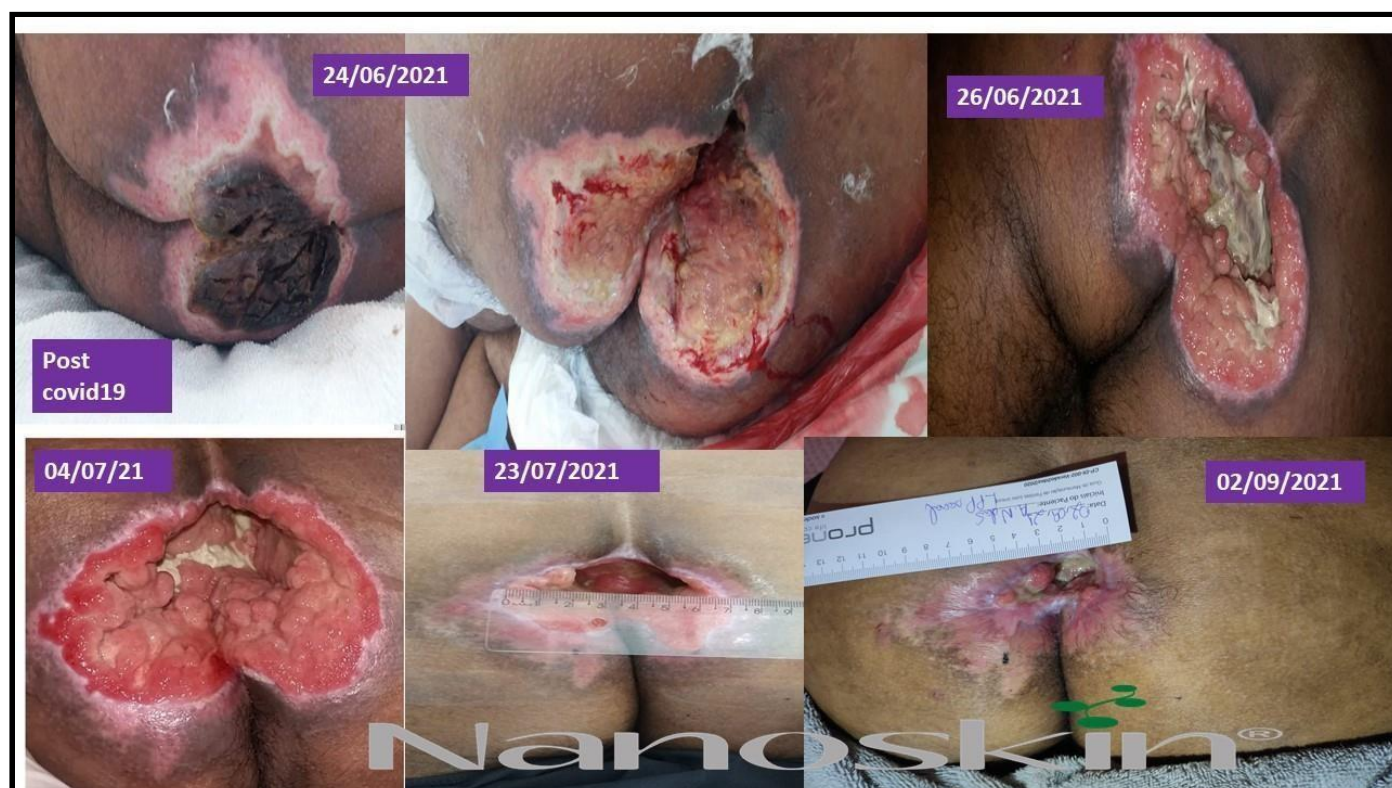3 Results and Discussion

In Vivo Analysis-

Patient (A.S), MALE, 43 YEARS OLD, WAS ADMITTED TO THE HOSPITAL BECAUSE OF COVID-19 at the beginning of May, incubated where he developed pressure ulcer. Then entered in Nanoskin

Clinical on 06/24/2021 under supervision of Dr. Pierre Basmaji, diagnosed with pressure ulcer size of 22x16 cm and 10 cm of depth.

The wound was necrosed and infected all over the wound. The advance dressing was used (Natural Nanoskin® ACT and Nanoskin soft) with antiseptic agents in 06/24/2021. On September 02/2021, after using the Nanoskin®ACT material in all days, it can be observed an excellent new tissue in the area of the wound and reduced wound area, and finally on 15/10/2021 completed healing (**Figure 1and 2**)



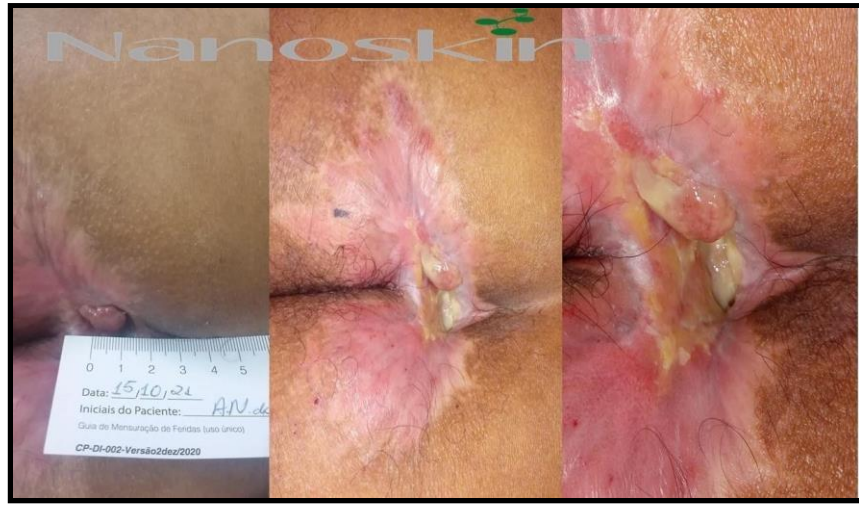

Figure 1 and 2: Complete wound healing with Covid-19 using Nanoskin-ACT.

Pilonidal Sinus Case

- Under Supervision of Dr. Bassam Noah – NeurospinalHospital

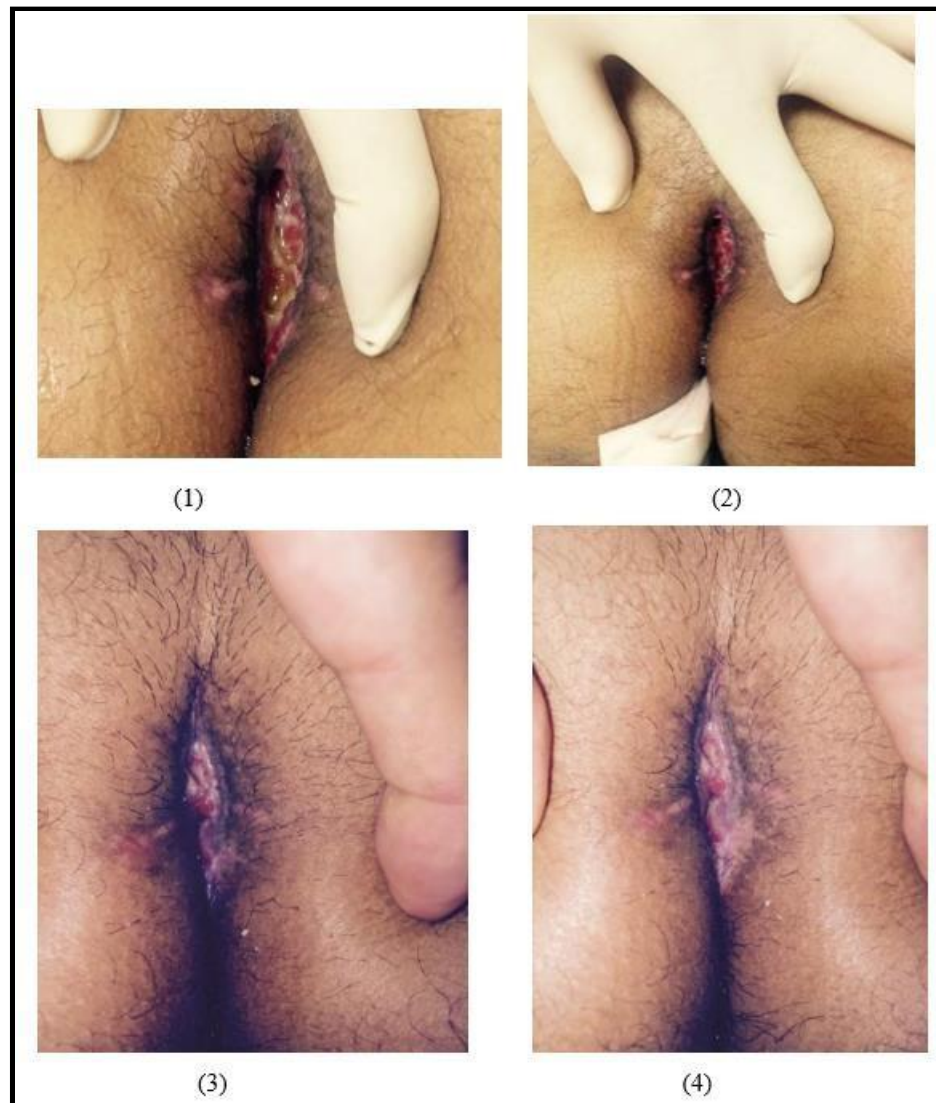


Figure 3: Complete wound healing in Pilonidal Sinus Case with Nanoskin-ACT.

Donor Site Case

- Under supervision of Dr. Amir – Al Fujairah Hospital
- Wound healed within 7 days and patient noted painless healing

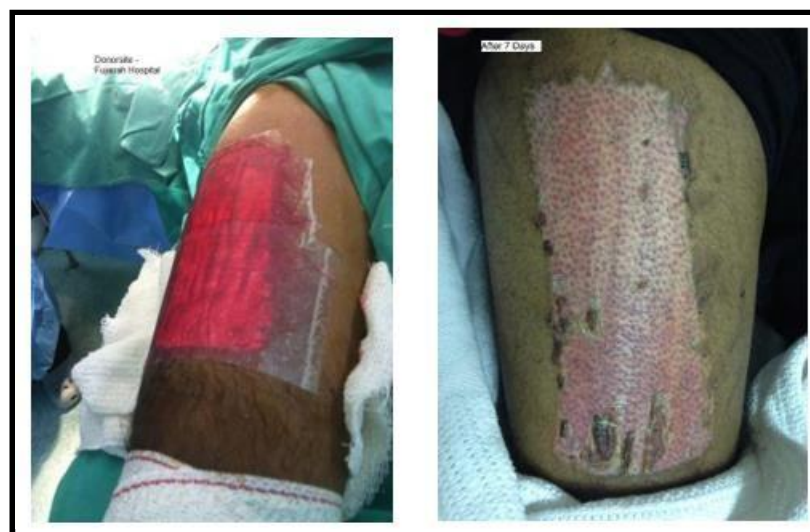
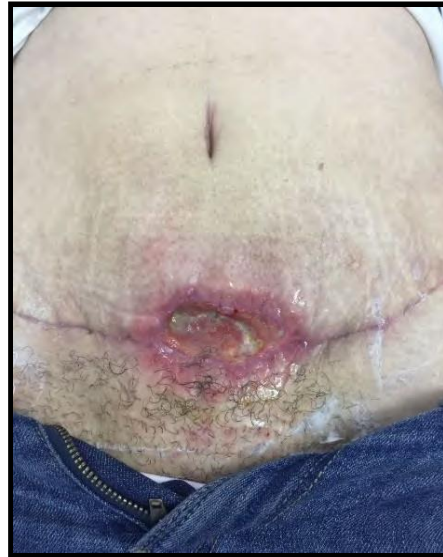
Figure 4: Complete wound healing in donor site case With Nanoskin-ACT.

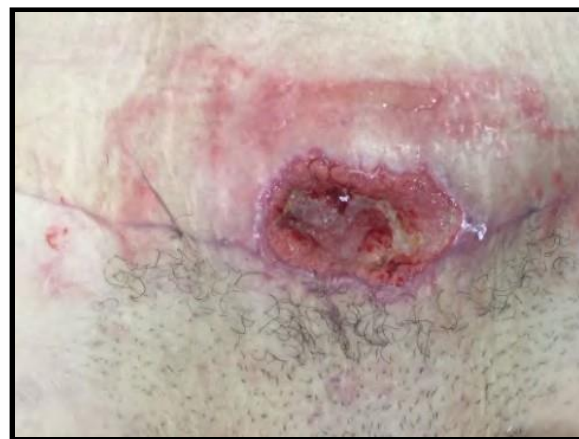Abdominoplasty siteinfection

- Under supervision of Dr. Amani – First Mediclinic



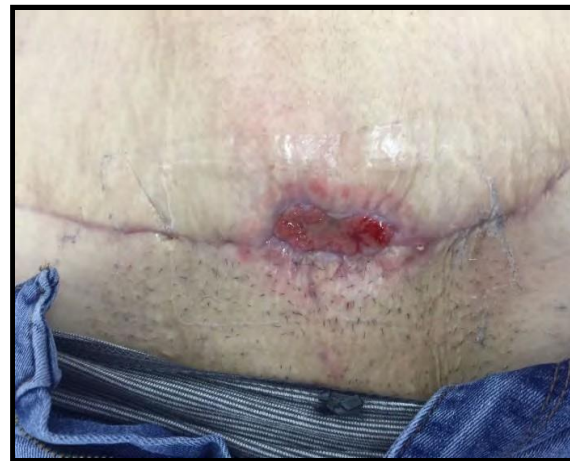1 – 01/07/2017

First Nanoskin ACT membrane applied



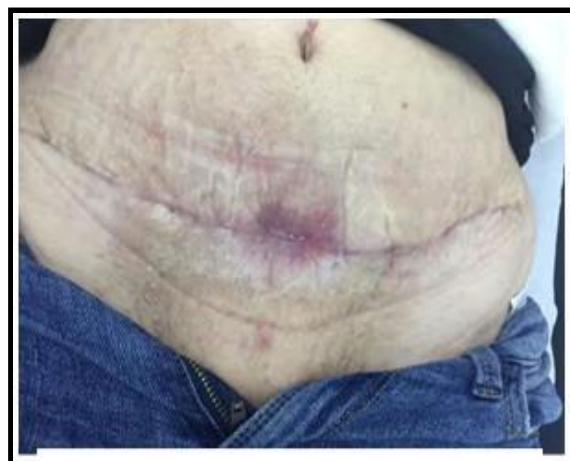2 – 03/07/2017

Second Nanoskin ACT membrane applied



3 – 09/07/2017

Last Nanoskin ACT membrane applied



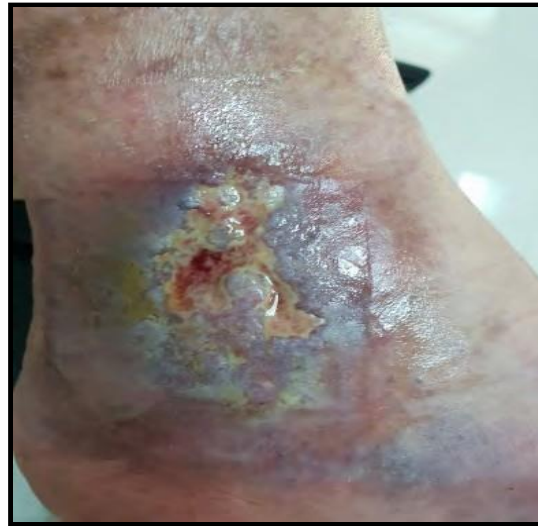4 – 30/08/2017

Follow up appointment : Complete wound closure and minimized scar tissue

Figure 5: Complete wound healing in Abdominoplasty site infection with Nanoskin-ACT

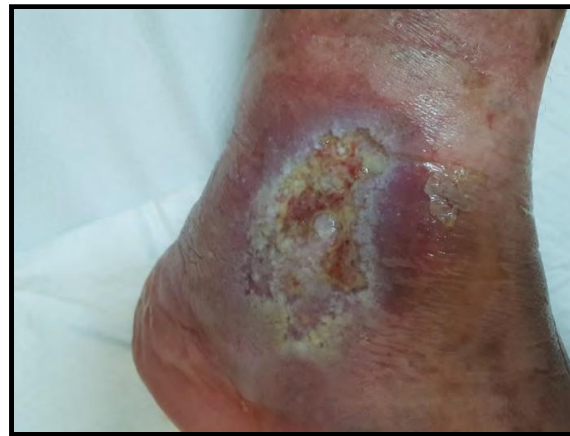Chronic Venous ulcer

- Male patient, 43 years old
- The wound was nonhealing for more than 6 months and it got infected
- Under supervision of Dr. Sobeh – Sobeh Clinic



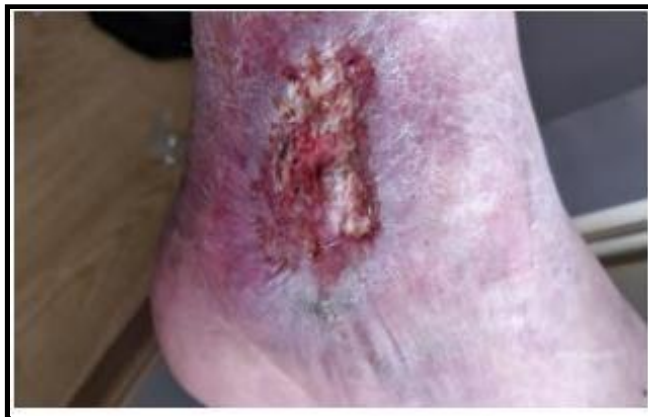1 – 10/06/2018

First application of Nanoskin ACT and Nanoskin ACT Soft



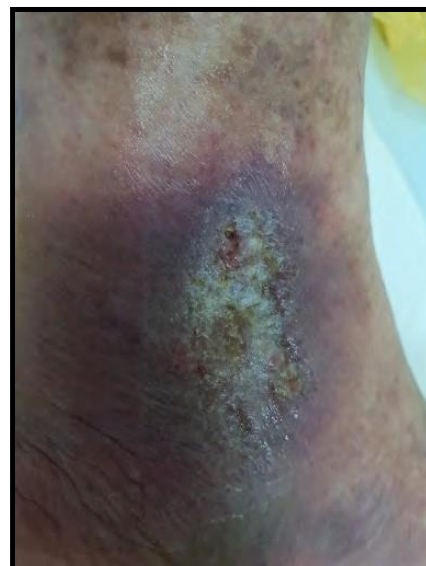2 – 12/06/2018

Second application of Nanoskin ACT and Nanoskin ACT Soft



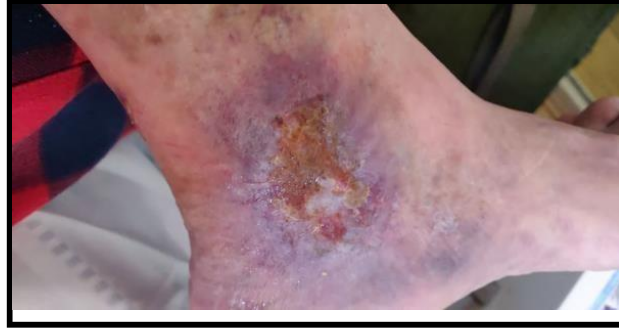3 – 21/06/2018

Patient left the country for a few days but he did the dressing change on his own every 3rd day. After he's back we apply Nanoskin ACT and soft again



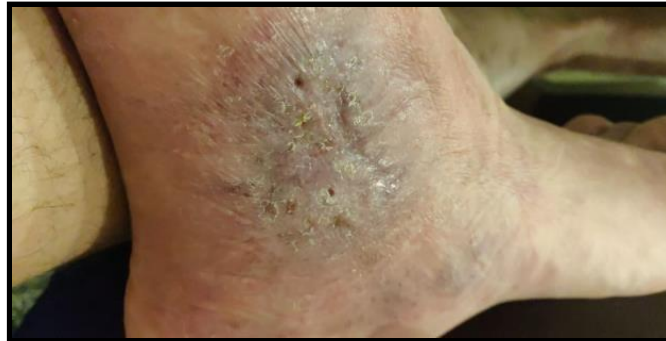4 – 16/07/2018

We resumed treatment with Nanoskin ACT after he was back again. Wound is showing progress



5 – 13/08/2018

Last application of Nanoskin ACT. Wound is clean and can move forward with Normal Nanoskin



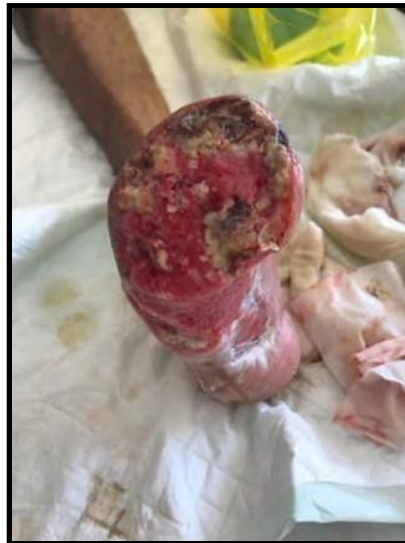6 – 27/08/2018

Venous ulcer is healed completely. Doctor Sobeh was impressed with the result, especially since the patient was travelling during the treatment

Figure 6: Complete wound healing with Nanoskin-ACT in Chronic Venous ulcer

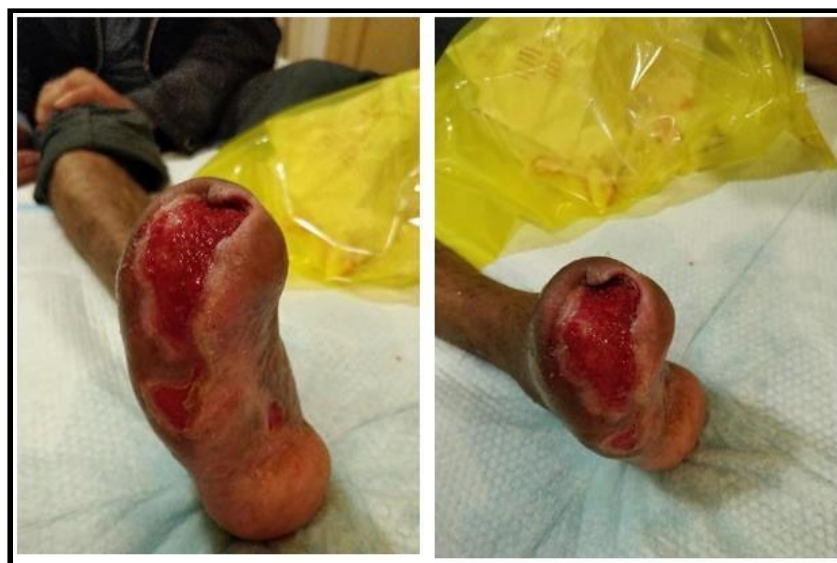Infected Diabetic Foot (Partial Amputation)

- A Diabetic Geriatric patient of 75 years old came to the first hospital with a complain of a spreading infection across the foot and necrotic toes. It was advised to amputate the leg. So he came to Burjeel Hospital for additional consolation. Doctors decided to save as much as possible and close the wound using Nanoskin ACT.
- Treatment with Nanoskin ACT and Nanoskin ACT Soft
- Under supervision of Dr. Bassel Safi – Burjeel Hospital Abu Dhabi



1 – 18/12/2018

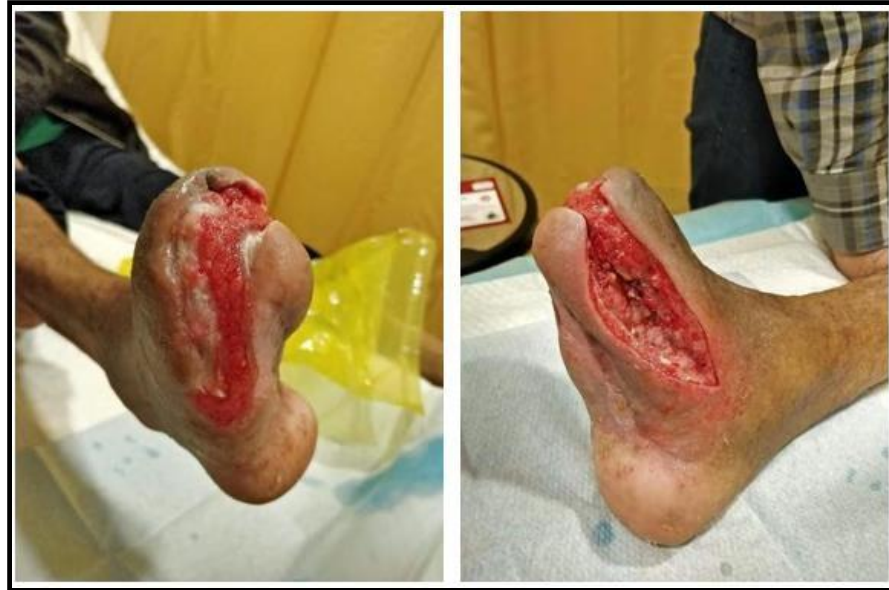Before Treatment With Nanoskin ACT & Nanoskin ACT Soft.



2 – 16/02/2019

During Treatment With Nanoskin ACT & Nanoskin ACT Soft (twice a week).

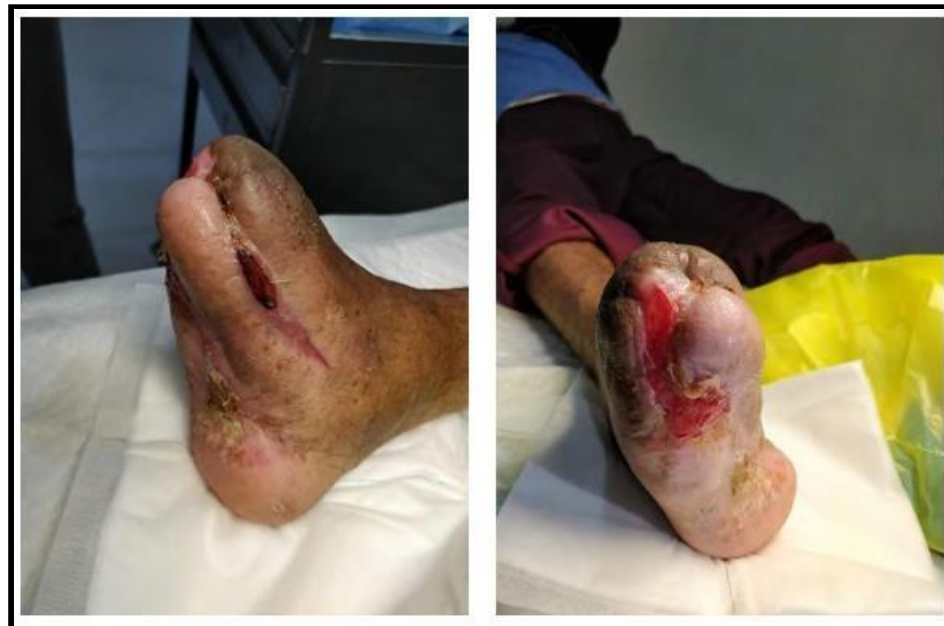In this stage, the doctor applies a layer of Nanoskin ACT Soft (to make sure the whole wound bed area is covered), followed by Nanoskin ACT Membrane.



3 – 06/03/2019

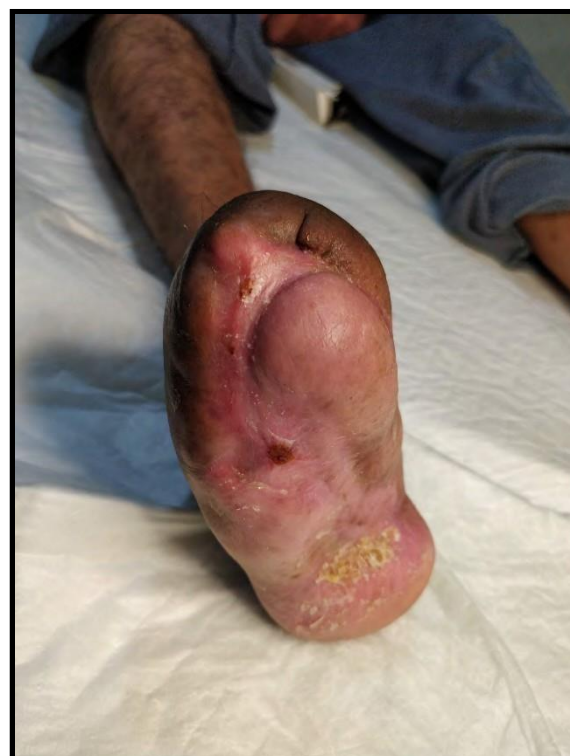During Treatment With Nanoskin ACT & Nanoskin ACT Soft (twice a week).

Doctor opted for further debridement of the mesial part of the leg. To completely remove infected tissue and allow regrowth of healthy tissue.



4 – 25/05/2019

Wound bed shrunk significantly in size, with healthy granulation tissue filling up the site & the mesial part completely healing



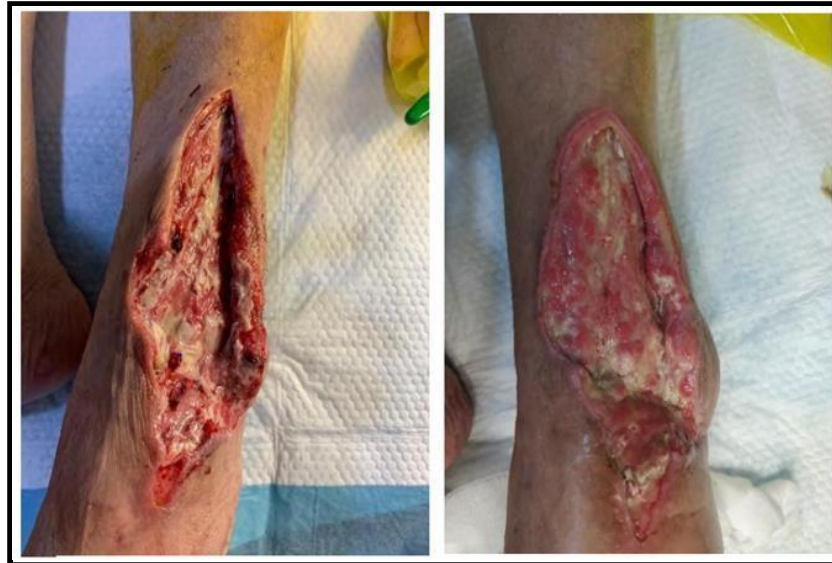5 – 18/06/2019

Complete healing and successfully saving the leg from amputation in a conservative approach with Nanoskin ACT

Figure 7: Complete Wound healing with Nanoskin-ACT in Infected Diabetic Foot (Partial Amputation)

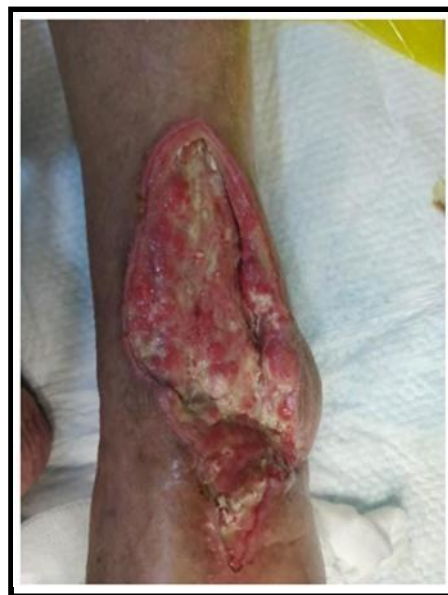NECROTIZING FASCIITIS CASE (flesh-eating disease)

- A Diabetic Geriatric patient of 80 years old complained of severe pain and swelling in leg area. The disease progressed and puss started coming out via 3 littleholes.
- Patient has history of multiple systemic complications as well
- A Surgery was performed to clean and debride the lost tissue.
- Treatment with Nanoskin ACT and Nanoskin ACT Soft.
- Under supervision of Dr. Bassel Safi – Burjeel Hospital Abu Dhabi



1 – 12/03/2019

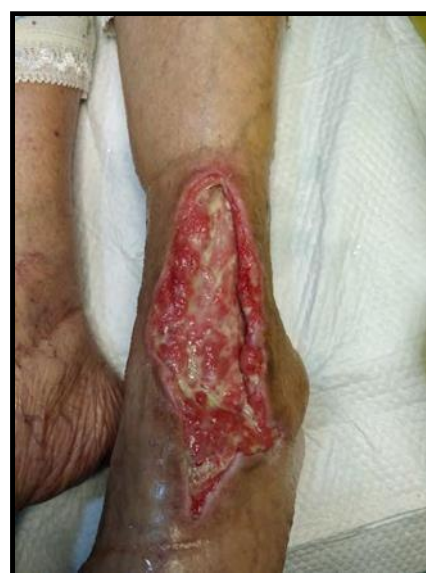Before Treatment With Nanoskin ACT & Nanoskin ACT Soft. First Application



2 – 26/03/201

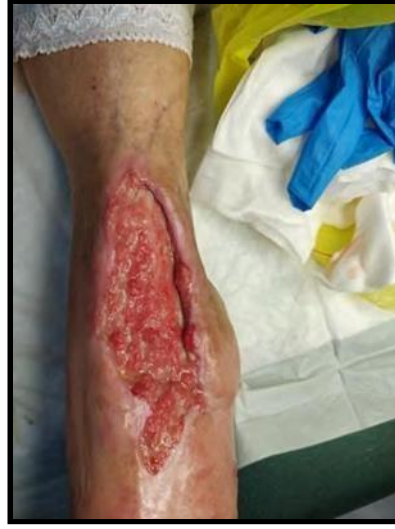During Treatment With Nanoskin ACT & Nanoskin ACT Soft (alternate day dressing change.)

In this stage, the doctor applies a layer of Nanoskin ACT Soft (to make sure the whole wound bed area is covered), followed by Nanoskin ACT Membrane.



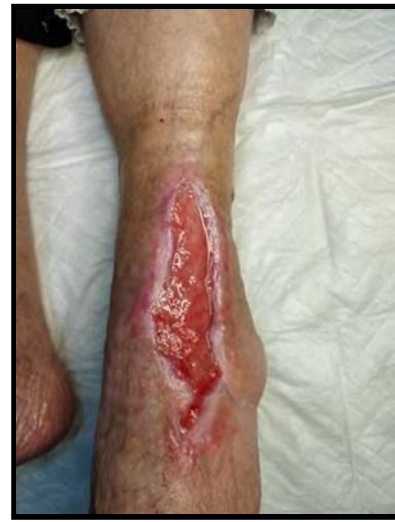3 – 03/04/2019

During Treatment With Nanoskin ACT & Nanoskin ACT Soft.



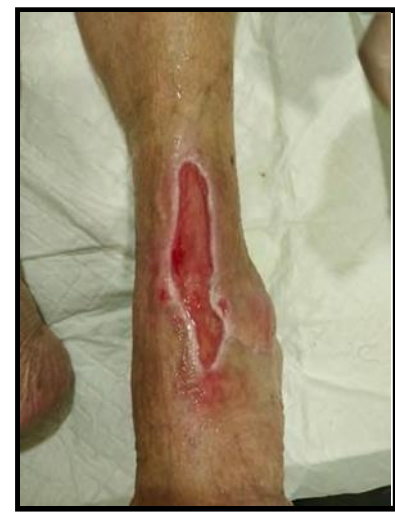4 – 29/05/2019

During Treatment With Nanoskin ACT & Nanoskin ACT Soft. The doctor makes small debridement where necessary



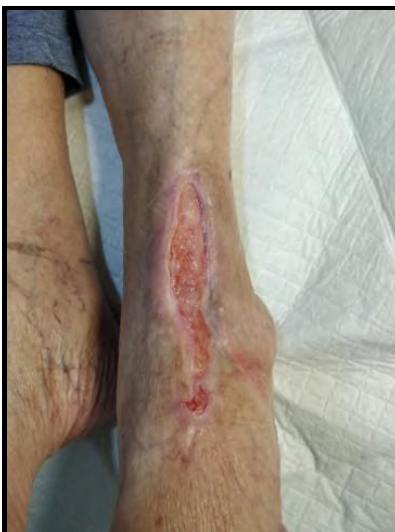5 – 08/07/2019

Wound bed shrunk significantly in size, with healthy granulation tissue filling up the site. At this stage, we use Nanoskin ACT Membrane only, 2 times a week



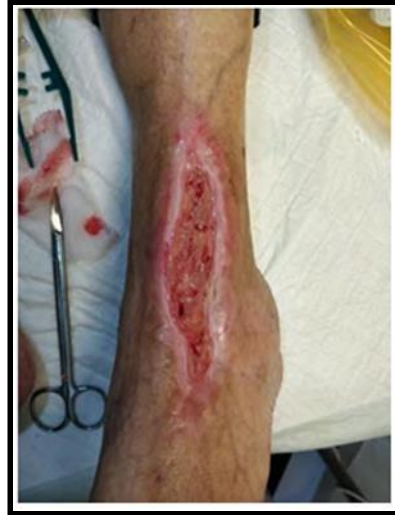6 – 29/08/2019

During Treatment with Nanoskin ACT. Doctor opted for changing the dressing once a week.



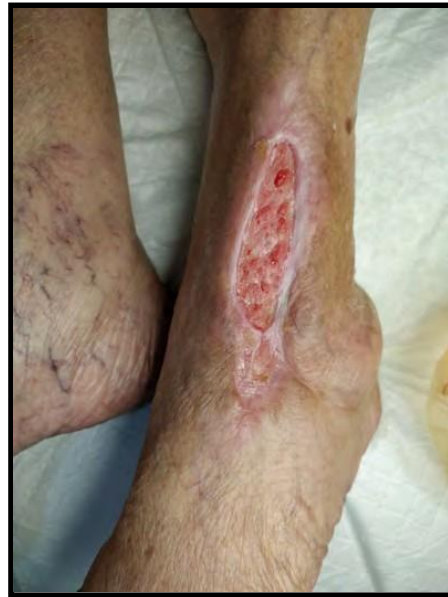7 – 22/09/2019

During Treatment with Nanoskin ACT. Wound almost healed, and the need for skin graft was avoided entirely.



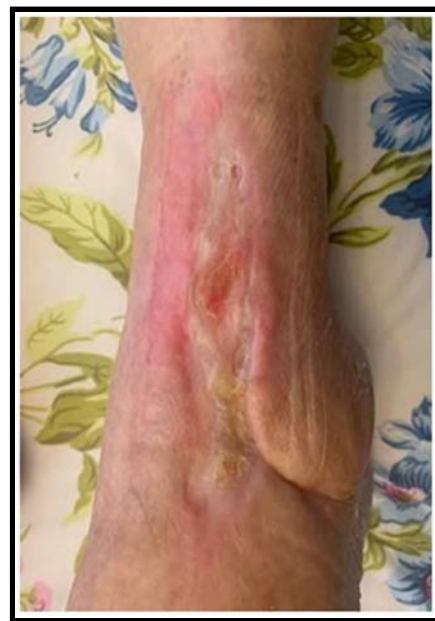8 – 20/10/2019

During Treatment with Nanoskin ACT. Doctor opted for local debridement of the wound bed as a stimulant for the process



9 – 18/11/2019

Visible decrease in wound size, Doctor attributes slow epithelization to patient's age and diabetic condition



10 – Follow up appointment

Wound completely healed without having to let 80 years old patient undergo a skin graft operation

Figure 8: Complete wound healing with NECROTIZING FASCIITIS CASE (flesh-eating disease) using Nanoskin-ACT

Conclusion

Bacterial cellulose was successfully modified by changing the fermentation medium with Brassica Nigra extract, which produced suitable Natural Nanoskin® Membranes (Bacterial cellulose) for use in general wound healing area.

Nanoskin® (Bacterial cellulose) shows several applications of natural

material in wounds application. Clinical cases with recent covid-19 and chronic wounds are details and treatment were successfully.

In conclusion, Nanoskin®(Bacterial cellulose membranes) applies for different wound healing treatment, since skin cancer, covid- 19 and several chronic and rare wounds.

References

1. Olyveira GM, Costa LMM, Riccardi CS, Santos ML, Daltro PB, et al. (2016) Bacterial Cellulose for Advanced Medical Materials. In: Grumezescu, A.M., Ed., Nano biomaterials in Soft Tissue Engineering, Elsevier, Romania. 5:57-82.
2. Olyveira GM, Santos ML, Costa LMM, Daltro PB, Basmaji P, et al. (2014) Bacterial Biocomposites for Guided Tissue Regeneration. *Science of Advanced Materials*. 6(12): 2673-2678.
3. de Olyveira GM, Santos ML, Costa LMM, Daltro PB, Basmaji P, et al. (2015) Physically Modified Bacterial Cellulose Biocomposites for Guided Tissue Regeneration. *Science of Advanced Materials*. 7(8): 1657-1664.
4. de Olyveira GM, Basmaji P, Costa LMM, Dos Santos ML, Dos Santos Riccardi C, et al. (2017) Surface Physical Chemistry Properties in Coated Bacterial Cellulose Membranes with Calcium Phosphate. *Materials Science & Engineering. C, Materials for Biological Applications*. 75: 1359-1365.
5. Kaminagakura KLN, Sue Sato S, Sugino P, Kataki de Oliveira Veloso L, Dos Santos DC, et al. (2019) Nanoskin® to treat full thickness skin wounds. *J Biomed Mater Res B Appl Biomater*. 107(3): 724-732.
6. Viveiros MMH, Rainho CA, Ramirez JAZ, Kaneno R, Silva MG, et al. (2022) Physical, functional and biochemical features of Nanoskin® bacterial cellulose scaffold as a potential carrier for cell transference. *Materials Letters*. 308(Part A): 131109.
7. Basmaji P, Molina De Olyveira GM, Kanjou M (2021) Skin Cancer Treatment by Nanoskin Cellulose: Future Cancer Wound Healing. *Journal of Biomaterials and Nanobiotechnology*. 12(1): 1-6.
8. Al Mualla S, Al Nabooda M, Salman N, Basmaji P, De Olyveira G, et al. (2018) Special Nanoskin-ACT-Biological Membranes from Deep Wounds. *Journal of Biomaterials and Nanobiotechnology*. 9(1): 79-88.
9. Kanjou MM, Abdulhakim H, Olyveira G, Basmaji P (2019) 3-D Print Celulose Nanoskin: Future Diabetic Wound Healing. *Journal of Biomaterials and Nanobiotechnology*. 10(4): 190-195.
10. Basmaji P (2020) First Breast Cancer Treatment Naturally by Nanoskin Act. *Journal of Biomaterials and Nanobiotechnology*. 11(3): 179-187.
11. El-Hoseny S, Basmaji P, Olyveira G, Costa L, Alwahedi A, et al. (2015) Natural ECM-Bacterial Cellulose Wound Healing—Dubai Study. *Journal of Biomaterials and Nanobiotechnology*. 6(4): 237- 246.
12. Mualla S, Farahat R, Basmaji P, Olyveira G, Costa L, et al. (2016) Study of Nanoskin ECM-Bacterial Cellulose Wound Healing/United Arab Emirates. *Journal of Biomaterials and Nanobiotechnology*. 7(2): 109-117.
13. Basmaji P, De Olyveira GM, Kanjou M, Reichert H (2022) Bacterial Cellulose for Several Medicine Areas: Future Insights. *Journal of Biomaterials and Nanobiotechnology*. 13(1): 1-23.